Thoracic aortic aneurysm formation with the use of $CaCl_2$: an experimental model in rabbits

Vasiliki Androutsopoulou[1], Despina N. Perrea[1], Nikolaos Kavantzas[2], Dimitrios C. Angouras[3], Ilias P Doulamis[1], Aspasia Tzani[1], Dimitrios C. Iliopoulos[1]

[1]*Laboratory of Experimental Surgery and Surgical Research "N.S. Christeas", National and Kapodistrian University of Athens, Medical School, Athens, Greece.*
[2]*1st Department of Pathology, National and Kapodistrian University of Athens, Medical School, Laiko University Hospital, Athens, Greece*
[3]*Department of Cardiothoracic Surgery, National and Kapodistrian University of Athens, Medical School, "Attikon" University Hospital, Athens, Greece*

Abstract

Introduction: Thoracic aortic aneurysms (TAA) remain a serious condition with both high morbidity and mortality rates. Further understanding of the pathophysiology and progression of TAAs may provide less invasive diagnostic techniques and therapeutic strategies in patients with this alarming disease. The objective of the present study was to establish a reproducible rabbit model of thoracic aortic aneurysm with the use of $CaCl_2$.

Methods: Adult New-Zealand rabbits were subjected to posterolateral thoracotomy and were allocated into 2 groups: Control group (n=4): a NaCl solution was applied on the external wall of descending thoracic aorta (sham surgery), and $CaCl_2$-treated group (n=8): a solution of 0.5 mol/L CaCl2 was applied on the external wall of descending thoracic aorta.

Results: Twelve weeks of $CaCl_2$ treatment resulted in an average 21% increase in the aortic diameter (4876±617 μm vs 3856±604 μm, p= 0.022) and in an decrease in wall thickness(366±107 vs 280±72, p>0.05) compared to the aorta segments of untreated animals. Although no statistical significance was achieved, aortas treated with $CaCl_2$ presented apparent atherosclerosis in 75% of the cases, while only 20% of the control aortas were found atherosclerotic.

SUBMISSION: 04/05/2018 | ACCEPTANCE: 11/06/2018

Citation

Androutsopoulou V, Perrea DN, Kavantzas N, Angouras DC, Doulamis IP, Tzani A, Iliopoulos DC. Thoracic aortic aneurysm formation with the use of $CaCl_2$: an experimental model in rabbits. *Hell J Atheroscler* 2018; 9: 32-40

*Corresponding author: Aspasia Tzani, MD
Laboratory of Experimental Surgery and Surgical Research "N.S. Christeas", National and Kapodistrian University of Athens, Medical School, Athens, Greece
Agiou Thoma 15b, Goudi, Athens, 11527 Greece
e-mail: asptzani@gmail.com

© 2018 Hellenic Atherosclerosis Society

Conclusions: This study demonstrates for the first time the creation of a reproducible animal model of TAA in rabbits that recapitulates pathological changes attributed to humans.

Key words: thoracic aneurysm; rabbits; CaCl2; aorta; animal model

Introduction

There is currently an upward trend in the incidence thoracic aortic aneurysms (TAA), while there are approximately 5.9 cases per 100,000 person-years [1]. TAAs are mainly asymptomatic and they are discovered in routine checkups or after their incident complications such as rupture, dissection and sudden death [2]. Their masked phenotype makes them extremely dangerous, justifying, thus, their high mortality rate. Although a wide range of risk factors such as hypertension, smoking, chronic obstructive pulmonary disease, chronic aortic dissection, trauma, inflammatory and congenital diseases have been identified, the exact cause remains indistinct [1]. It is suggested that a degeneration of all three layers of the aorta (intima, media, adventitia) –mainly the first two- leads to a permanent localized dilation (over 50% of the normal diameter) of the artery [1].

The lack of knowledge regarding the exact pathways of TAA formation, prognosis and prevention constitutes the need for experimental models of TAA imperative. Aim of this study is to present a novel experimental model for TAAs.

Materials And Methods

Animals

8-week-old New Zealand male adult rabbits and 3-4 kg in weight were obtained from a certified breeding farm in Greek territory. Animals were housed in single metal cages and had access to tap water and standard balanced rabbit chow ad libitum. Room temperature ranged between 20 and 22°C, relative humidity ranged between 55 and 65%, and the light/dark cycle was 6 a.m./6 p.m. All possible precautions were taken to avoid animal suffering at each stage of the experiment. The experimental protocol was approved by the "Scientific Committee for the approval of protocols using animals for scientific purposes" established in the Laboratory for Experimental Surgery and Surgical Research "N.S. Christeas" of Athens Medical School and by the competent Veterinary Directorate of Attica Region. The protocol was in compliance with EU legislation (Directive 2010/63/EU) regarding the use of animals in biomedical science. Before enrollment in the protocol, animals were acclimatized for a period of 3 weeks.

Twelve rabbits (n=12) were allocated into 2 groups: Control group (n=4): animals were subjected to posterolateral thoracotomy and NaCl application on the external wall of descending thoracic aorta (sham surgery), while intervention group (n=8) underwent posterolateral thoracotomy and a solution of 0.5 mol/L $CaCl_2$ was applied on the external wall of descending thoracic aorta. Euthanasia of the animals followed after 12 weeks of the initial operation.

Surgical Procedure

Animals were initially sedated by intramuscular injection of 25-mg/kg ketamine and 5-mg/kg xylazine. They were then intubated and connected to a volume-controlled ventilator. Intubation was labored due to the distinct anatomy of airway in rabbits. VET-TUBEs were used for the intubation of the animals, and their size was respective to the body weight of each animal. Mechanical ventilation was adjusted to 28-30 breaths/min. Anesthesia was maintained by the intravenous administration of 30-50 mg/kg sodium thiopental via ocular vein. 100 mL of normal saline were administrated in each animal for hydration and recovery of blood loss. Left posterolateral thoracotomy was made through an incision on 4th intercostal space on the back. After

© 2018 Hellenic Atherosclerosis Society

entering pleural cavity, descending thoracic aorta was revealed from the site of the origin of left subclavian up to diaphragm with meticulous removal of adjacent tissues. Afterwards, a gauze moistened with $CaCl_2$ dilution (0.5 mol/L) or 0.9% NaCl was applied on the periadventital surface of the aorta. Pleural cavity was rinsed with normal saline in order to avoid adhesions. Strict layered closure was utilized for chest wall closure. A chest tube was not used, because the animals could not tolerate it. In order to avoid pneumothorax, pericostal suturing was made under Valsava maneuver. Animal was awakened and extubation followed. After surgery, each animal remained under close observation for one hour and then it was transferred to its cage. Feeding was initiated later during the same day. Pentobarbital was used for euthanasia. Two doses of enrofloxacin were administrated; one intra-operative and one on the first post-operative day.

Sham surgery

Sham surgery was identical to the aforementioned except for the application of 0,5 mol/L $CaCl_2$ solution, which was substituted with normal saline. Mean operative time was 40 minutes and it was comparable between both surgical procedures.

Histopathological examination

Following euthanasia, descending aorta was immediately fixed in 10% formalin at room temperature for 24 h. The tissue was then embedded in paraffin, sectioned and mounted on glass microscope slides. The sections were stained with hematoxylin eosin and examined using light microscopy by two independent researchers who were blinded to the randomization scheme.

Vascular tissue was studied and the following parameters were evaluated:

1) Maximum diameter of the vessel
2) Wall thickness of the vessel
3) Presence of atheromatosis
4) Thickness of the atheromatic plaque

Statistical analysis

Data are expressed as mean ± 1 standard deviation for continuous variables and as frequency (% percentage) for qualitative data. The normality of the distributions was assessed with Kolmogorov-Smirnov's test and graphical methods.

Comparisons between more than two groups were performed with Analysis of Variance (ANOVA) using Least Significant Difference (LSD) post-hoc test. ANOVA was used to test for group differences in all examined variables apart from urea % increase.

Mann-Whitney's U test was utilized as a non-parametric test for group comparisons regarding urea % increase after I/R induction.

A false discovery rate of 5% was controlled with a Benjamini-Hochberg p value correction.

Chi-square test was used for analysis of dichotomous variables.

All tests were two-sided. Differences were considered as statistically significant if the null hypothesis could be rejected with >95% confidence ($p<0.05$).

All statistical analyses were conducted in SPSS (version 21 for Mac OS; SPSS, Inc., Chicago, IL, USA).

Results

Histology

Twelve weeks of $CaCl_2$ treatment resulted in dilation of the exposed distal descending thoracic aortic segment (**Figure 1**). Pathological evaluation revealed disruption of the normal elastic lamellar architecture of the $CaCl_2$-exposed aortic wall compared to the contralateral wall or untreated control aorta (**Figures 1A-F**).

Aortic Diameter

$CaCl_2$ application on the aortas led to an average 21% diameter increase compared to the cohort of untreated animals (4876 ± 617 μm vs 3856 ± 604 μm, respectively, $p= 0.022$) (**Figure 2A**).

Wall Thickness

The proximal descending thoracic aorta showed significant thinning of the overall wall in $CaCl_2$ treated group. (**Figure 2B**). The segment of aorta

 © 2018 Hellenic Atherosclerosis Society

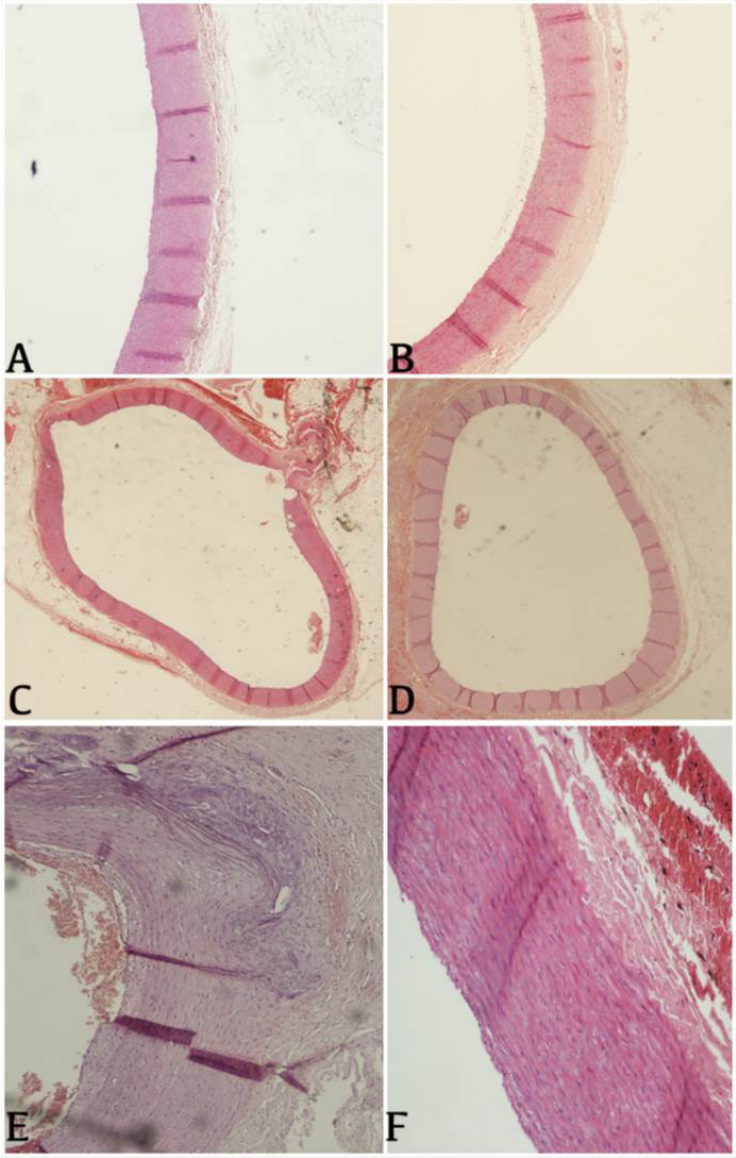

Figure 1. *Histological comparison of control and $CaCl_2$-treated descending thoracic aorta at 12 weeks. Hematoxylin and eosin staining of aorta tissue. Top, confocal images showing decreased wall thickness of aneurysmal aorta* ***(A)*** *and normal wall thickness of control aorta* ***(B)****. Medium, transverse slides showing diluted* ***(C)*** *and normal* ***(D)*** *aorta rings. Bottom, presence of atherosclerotic plaque in $CaCl_2$-treated aortas* ***(E)****, in contrast with normal aorta* ***(F)****.*

exposed to $CaCl_2$ was found to have a non-significant 23% decrease in total wall thickness compared to the untreated control group (366 ± 107 vs 280 ± 72, respectively, $p>0.05$). In addition, the mean wall thickness in the nonexposed or contralateral side of the $CaCl_2$-treated segment was unaffected and similar to the control group ($p>0.05$). Yet, when comparing the neat wall thickness (excluding the atherosclerotic plaque thickness), $CaCl_2$ treated group demonstrated decreased wall thickness (276 ± 61 μm vs 368 ± 63 μm for $CaCl_2$ and control group, respectively, $p=0.036$) (**Figure 2C**)

Atherosclerosis and plaque formation

Aortas treated with $CaCl_2$ presented apparent atherosclerosis in 75% of the cases, while only 20% of

the control aortas were found atherosclerotic, however statistical significance was not achieved. Mean plaque thickness was 34.5% lower in the control group than the intervention group (84 ± 136 μm vs 113 ± 126 μm, $p>0.05$). (**Figure 2D**) Additionally, after calculation of the % plaque thickness (plaque thickness/vessel diameter %), a higher index –yet not significant- was generated for $CaCl_2$ group than control (26.5 ± 30% vs 19.8 ± 32%, respectively; $p>0.05$)(**Figure 2E**).

Discussion

The impact of TAAs on healthcare system is considerable, since their prevalence is 5.9 per 100,000 per year and death rate reached 0.7/100,000 population per year [3, 4]. Rupture is the predominant cause of death and in the majority no previous symptoms are present. Gold-standard for the treatment of operable TAAs is open surgical repair, while endovascular approach (endovascular aortic repair, EVAR) exhibits promising results, especially in high-risk profile patients [5-7]. Yet, mortality of both procedures is relatively high, 10-12%, respectively, while risk for complications such as acute renal failure, myocardial ischemia, respiratory failure, post-operative bleeding and paraplegia [8, 9]. Hence, it is indisputable that TAAs are accompanied with a high mortality and morbidity rate, emerging the need for further understanding of the formation and progression of TAAs so that more efficient therapeutic strategies can be achieved. However, existing bibliography concerning efficient and reproductive experimental models for the study of TAAs is scarce.

Our findings indicate that application of $CaCl_2$ on the outside wall of descending thoracic aorta via posterolateral thoracotomy, resulted in increased diameter and decreased wall thickness of the vessel. Yet, these changes were not accompanied with atheromatosis or atherosclerosis.

This is the first study, to our knowledge, investigating the effect of $CaCl_2$ application on the external wall of the thoracic aorta of rabbits and its association with aneurysmatic degeneration. Previous studies report on the use of $CaCl_2$ for TAA formation in rodent models [10], while in the case of rabbits, elastase administration is better-documented [11-13]. High affinity of calcium for elastin results into calcium-elastic tissue complex which in turn weakens the vessel wall and leads to the development of aneurysm [14]. Data from in vivo studies indicate a correlation between inflammatory infiltration and aneurysmatic dilation of the vessel diameter [14, 15]. This complex can also facilitate the initiation of focal inflammatory and arteriosclerotic reaction of the aortic wall and subsequent aortic aneurysm development [11].

Gertz et al. [14] were the first to describe a $CaCl_2$-induced aneurysm model in the carotid artery of rabbits. Further studies reporting on the use of $CaCl_2$ for aneurysm induction in rabbits, showed data regarding abdominal aorta [16, 17]. Yet, it was not validated if these results are applicable on the case of thoracic aorta, since the aorta develops from diverse origins and it is assumable that the biology of TAA formation may differ from that in the abdomen [11].

Ikonomidis et al. [10], described a murine model of $CaCl_2$-induced TAA, which was characterized by increased diameter and decreased wall thickness of the treated vessel. A similar approach was adopted by Shen et al. [18] who applied this technique on MMP-2 KO mice. Concerning the application of $CaCl_2$ on rabbit aorta, Bi et al. [11], proposed a novel model of combined administration of elastase and $CaCl_2$ on abdominal aorta in rabbits. The authors showed the largest increase in aortic diameter 30 days after treatment with the aforementioned agents.

Elastase administration on rabbit thoracic aortas has been extendedly described [16, 17, 19]. It is associated with relatively fast induction of aneurysm formation which partially recovers after treatment. Elastase has also been combined with $CaCl_2$ in the formation of AAA, resulting in increased aortic dilation compared to this of each component separately [11]. Moreover, Bi et al. [11] proposed a model of AAA induced by the combination of periaortic elastase administration

 © 2018 Hellenic Atherosclerosis Society

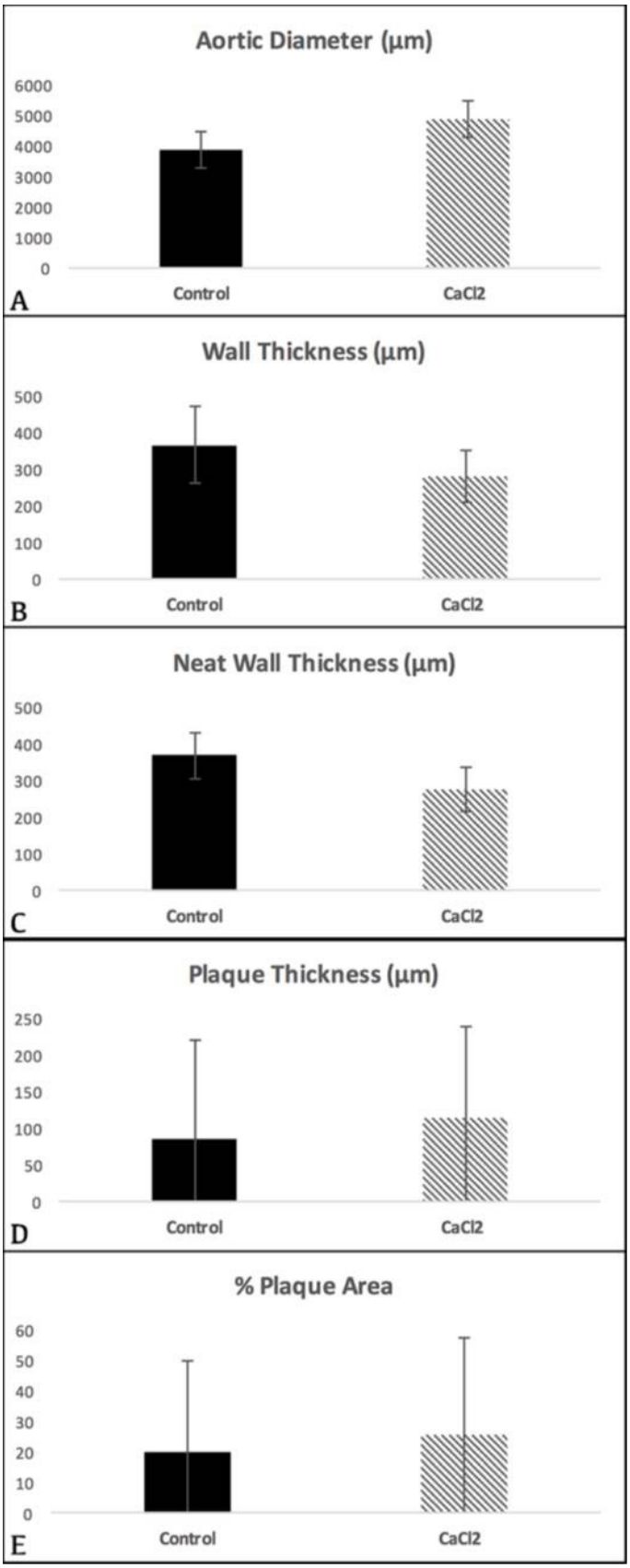

Figure 2. *Histological evaluation of aortic damage in $CaCl_2$-treated group*
A. *Diameter of descending thoracic aorta in control and $CaCl_2$-treated groups.* ***B.*** *Thickness of descending thoracic aorta wall thickness in control and $CaCl_2$-treated groups.* ***C.*** *Thickness of descending thoracic aorta neat wall thickness (excluding the atherosclerotic plaque thickness) in control and $CaCl_2$-treated groups.* ***D.*** *Plaque thickness of descending thoracic aorta in control and $CaCl_2$-treated groups.* ***E.*** *Percentage of plaque/vessel lumen area of the descending thoracic aorta in control and $CaCl_2$-treated groups.*

© 2018 Hellenic Atherosclerosis Society

and aortic coarctation, which led in a slowly progressive but sustained aneurysmatic dilation of the abdominal aorta.

In conclusion, we propose a feasible, efficient and reproducible way to create rapid dilation of rabbit thoracic aortic arteries to form a model of TAA. This model is suitable for experimental $CaCl_2$-induced TAA formation, which could be valuable for elucidating TAA mechanisms and therapeutic interventions, especially through drug-eluting stents or stent graft-mediated gene delivery system in experimental studies.

Funding
This research received no specific grant from any funding agency in the public, commercial, or not-for-profit sectors.

Declaration of Interests
The authors report no conflicts of interest. The authors alone are responsible for the content and writing of the paper.

Acknowledgements:
None

Περίληψη

Δημιουργία ανευρύσματος θωρακικής αορτής με την χρήση χλωριούχου ασβεστίου: Πειραματικό μοντέλο σε κονίκλους

Βασιλική Ανδρουτσοπούλου[1], Δέσποινα Περρέα[1], Νικόλαος Καβαντζάς[2], Δημήτριος Αγγουράς[3], Ηλίας Δουλάμης[1], Ασπασία Τζανή[1], Δημήτριος Ηλιόπουλος[1]

[1]*Εργαστήριο Πειραματικής Χειρουργικής και Χειρουργικής Ερεύνης "Ν.Σ Χρηστέας", Ιατρική Σχολή Αθηνών, Εθνικό και Καποδιστριακό Πανεπιστήμιο Αθηνών*
[2]*Εργαστήριο Παθολογικής Ανατομικής, Ιατρική Σχολή Αθηνών, Εθνικό και Καποδιστριακό Πανεπιστήμιο Αθηνών*
[3]*Καρδιοχειρουργική Κλινική, "Αττικόν Νοσοκομείο", Ιατρική Σχολή Αθηνών, Εθνικό και Καποδιστριακό Πανεπιστήμιο Αθηνών*

Εισαγωγή: Τα ανευρύσματα της θωρακικής αορτής (ΑΘΑ) παραμένουν μια σοβαρή κατάσταση με υψηλά ποσοστά νοσηρότητας, αλλά και θνησιμότητας. Η περαιτέρω κατανόηση της παθοφυσιολογίας και της εξέλιξης των ΑΘΑ κρίνεται απαραίτητη για την ανακάλυψη λιγότερο επεμβατικών διαγνωστικών τεχνικών και θεραπευτικών στρατηγικών σε ασθενείς με την δυνητικά θανατηφόρα αυτή ασθένεια. Σκοπός της παρούσας μελέτης ήταν η δημιουργία ενός αναπαραγώγιμου μοντέλου ανευρύσματος θωρακικής αορτής σε κονίκλους με τη χρήση χλωριούχου ασβεστίου ($CaCl_2$).
Υλικό και Μέθοδος: Ενήλικοι κόνικλοι Νέας Ζηλανδίας υποβλήθηκαν σε οπίσθια θωρακοτομή και χωρίστηκαν σε 2 ομάδες: Ομάδα ελέγχου (η = 4): Εφαρμόστηκε διάλυμα χλωριούχου νατρίου (NaCl) στο εξωτε-

 © 2018 Hellenic Atherosclerosis Society

ρικό τοίχωμα της κατιούσας θωρακικής αορτής (χειρουργική επέμβαση ψευδαισθήσεων) και ομάδα που υποβλήθηκε σε αγωγή με $CaCl_2$ (η = 8): εφαρμόστηκε διάλυμα 0.5 mol / L $CaCl_2$ στο εξωτερικό τοίχωμα της κατιούσας θωρακικής αορτής.

Αποτελέσματα: Δώδεκα εβδομάδες θεραπείας με $CaCl_2$ οδήγησαν σε μέση αύξηση κατά 21% στην διάμετρο της αορτής (4876617 μm έναντι 3856604 μm, p = 0,022) και σε μείωση του πάχους του τοιχώματός της (366107 έναντι 28072, p> 0,05), σε σύγκριση με τα τμήματα της αορτής των κονίκλων στην ομάδα του χλριούχου νατρίου. Αν και δεν επιτεύχθηκε στατιστική σημαντικότητα, οι αορτές που υποβλήθηκαν σε αγωγή με $CaCl_2$ παρουσίασαν εμφανή αθηροσκλήρωση στο 75% των περιπτώσεων, ενώ μόνο το 20% των αορτών ελέγχου βρέθηκαν αθηροσκληρωτικές.

Συμπεράσματα: Η μελέτη αυτή παρουσιάζει για πρώτη φορά τη δημιουργία ενός ζωικού μοντέλου θωρακικού ανευρύσματος αορτής σε κονίκλους, που περιλαμβάνει τις ιστολογικές αλλοιώσεις που εμφανίζονται στους ανευρυσματικούς ασθενείς.

Λέξεις ευρετηρίου: ανεύρυσμα θωρακικής αορτής, χλωριούχο ασβέστιο, αορτή, κόνικλοι, ζωϊκό μοντέλο

*Στοιχεία υπεύθυνου συγγραφέα: Ασπασία Τζανή, MD
Εργαστήριο Πειραματικής Χειρουργικής και Χειρουργικής Ερεύνης "Ν.Σ Χρηστέας",
Ιατρική Σχολή Αθηνών
Αγίου Θωμά 15β, Γουδί , Αθήνα
e-mail: asptzani@gmail.com

References

1. Ernst CB. Abdominal aortic aneurysm. *N Engl J Med* 1993; 328: 1167-1172
2. Lio A, Nicolo F, Bovio E et al. Total Arch versus Hemiarch Replacement for Type A Acute Aortic Dissection: A Single-Center Experience. *Tex Heart Inst J* 2016; 43: 488-495
3. Lau C, Gaudino M, de Biasi AR et al. Outcomes of Open Repair of Mycotic Descending Thoracic and Thoracoabdominal Aortic Aneurysms. *Ann Thorac Surg* 2015; 100: 1712-1717
4. Coe TM, Wilson SE, Chang DC. Do past mortality rates predict future hospital mortality? *Am J Surg* 2016; 211: 159-165
5. Landenhed M, Engstrom G, Gottsater A et al. Risk profiles for aortic dissection and ruptured or surgically treated aneurysms: a prospective cohort study. *J Am Heart Assoc* 2015; 4: e001513
6. Glebova NO, Selvarajah S, Orion KC, et al. Fenestrated endovascular repair of abdominal aortic aneurysms is associated with increased morbidity but comparable mortality with infrarenal endovascular aneurysm repair. *J Vasc Surg* 2015; 61: 604-610
7. Roselli EE, Idrees JJ, Lowry AM, et al. Beyond the Aortic Root: Staged Open and Endovascular Repair of Arch and Descending Aorta in Patients With Connective Tissue Disorders. *Ann Thorac Surg* 2016; 101: 906-912
8. von Allmen RS, Gahl B, Powell JT. Incidence of Stroke Following Thoracic Endovascular Aortic Repair for Descending Aortic Aneurysm: A Systematic Review of the Literature with Meta-analysis. *Eur J Vasc Endovasc Surg* 2017; 53: 176-184
9. Dias-Neto M, Reis PV, Rolim D et al. Strategies to prevent TEVAR-related spinal cord ischemia. *Vascular* 2017; 25: 307-315
10. Ikonomidis JS, Gibson WC, Gardner J et al. A murine

© 2018 Hellenic Atherosclerosis Society

model of thoracic aortic aneurysms. *J Surg Res* 2003; 115: 157-163

11. Bi Y, Zhong H, Xu K et al. Performance of a modified rabbit model of abdominal aortic aneurysm induced by topical application of porcine elastase: 5-month follow-up study. *Eur J Vasc Endovasc Surg* 2013; 45: 145-152
12. Sasaki K, Ujiie H, Higa T, et al. Rabbit aneurysm model mediated by the application of elastase. *Neurol Med Chir* (Tokyo) 2004; 44: 467-473, discussion 473-474
13. Origuchi N, Shigematsu H, Izumiyama N, et al. Aneurysm induced by periarterial application of elastase heals spontaneously. *Int Angiol* 1998; 17: 113-119
14. Gertz SD, Kurgan A, Eisenberg D. Aneurysm of the rabbit common carotid artery induced by periarterial application of calcium chloride in vivo. *J Clin Invest* 1988; 81: 649-656
15. Anidjar S, Dobrin PB, Eichorst M, et al. Correlation of inflammatory infiltrate with the enlargement of experimental aortic aneurysms. *J Vasc Surg* 1992; 16: 139-147
16. Huang G, Wang A, Li X et al. Change in high-sensitive C-reactive protein during abdominal aortic aneurysm formation. *J Hypertens* 2009; 27: 1829-1837
17. Kobayashi H, Matsushita M, Oda K, et al. Effects of atherosclerotic plaque on the enlargement of an experimental model of abdominal aortic aneurysm in rabbits. *Eur J Vasc Endovasc Surg* 2004; 28: 71-78
18. Shen M, Lee J, Basu R et al. Divergent roles of matrix metalloproteinase 2 in pathogenesis of thoracic aortic aneurysm. *Arterioscler Thromb Vasc Biol* 2015; 35: 888-898
19. Matsushita M, Kobayashi H, Oda K et al. A rabbit model of abdominal aortic aneurysm associated with intimal thickening. *Eur Surg Res* 1999; 31: 305-313

 © 2018 Hellenic Atherosclerosis Society